Importanza dello studio del modello animale con Glicogenosi di Tipo III

Michela Ripolone, Raffaella Violano, Serena Pagliarani, Maurizio Moggio

Convegno AIG 2015 – 20/21/22 Novembre - Rimini

FONDAZIONE IRCCS CA' GRANDA
OSPEDALE MAGGIORE POLICLINICO
Sistema Sanitario Regione Lombardia

ASSOCIAZIONE ITALIANA MIOLOGIA
ITALIAN ASSOCIATION OF MYOLOGY

Glicogenosi

Glicogenosi epatiche

- Glicogenosi I - difetto glucoso-6-fosfatasi
- Glicogenosi III - difetto amilo-1,6-glucosidasi (enzima deramificante)
- Glicogenosi IV - difetto 1,4-1,6 transglucosidasi (enzima ramificante)
- Glicogenosi VI - difetto fosforilasi
- Glicogenosi IX - difetto fosforilasi chinasi

Glicogenosi muscolari

- Glicogenosi II - difetto α-glucosidasi (maltasi acida)
- Glicogenosi V - difetto miofosforilasi
- Glicogenosi VII - difetto fosfofruttochinasi.

Glicogenosi di tipo III-GSDIII

- La GSDIII è una rara malattia del metabolismo che causa un accumulo di glicogeno soprattutto nel fegato, nel muscolo scheletrico e nel cuore.
- I pazienti affetti da GSDIII presentano epatomegalia, ipoglicemia, iperlipidemia e ritardo della crescita. I pts adulti mostrano inoltre un progressivo coinvolgimento muscolare.
- La cardiomiopatia sintomatica non è comune ma la maggior parte dei pazienti mostra un'ipertrofia ventricolare sinistra.
- La gravità clinica nei pazienti GSDIII è molto variabile.

Enzima Deramificante GDE

L'enzima deramificante, insieme con la glicogeno fosforilasi, degrada il glicogeno in molecole di glucosio, rendendolo così disponibile per le necessità energetiche del metabolismo cellulare.

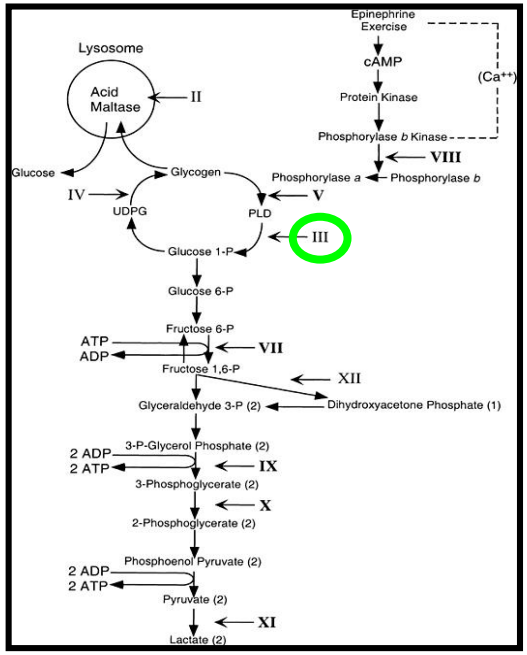

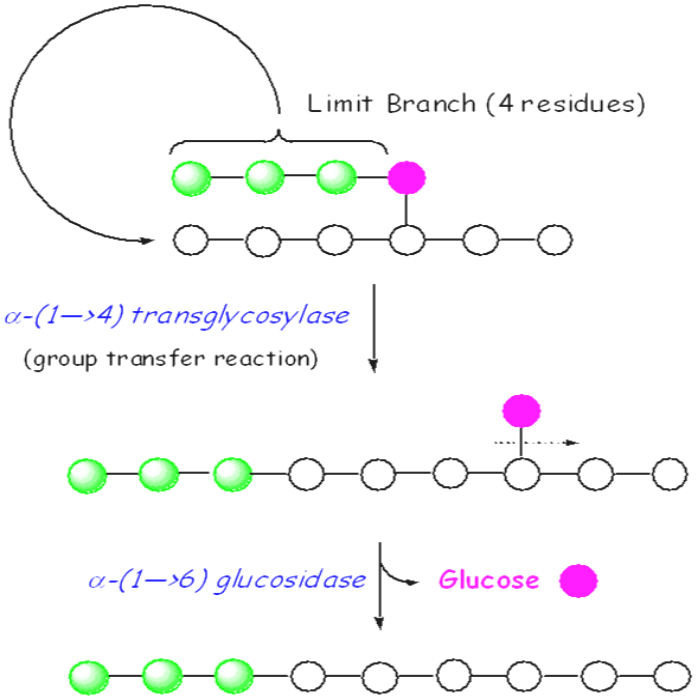

Mutazioni del gene AGL nella Popolazione Italiana

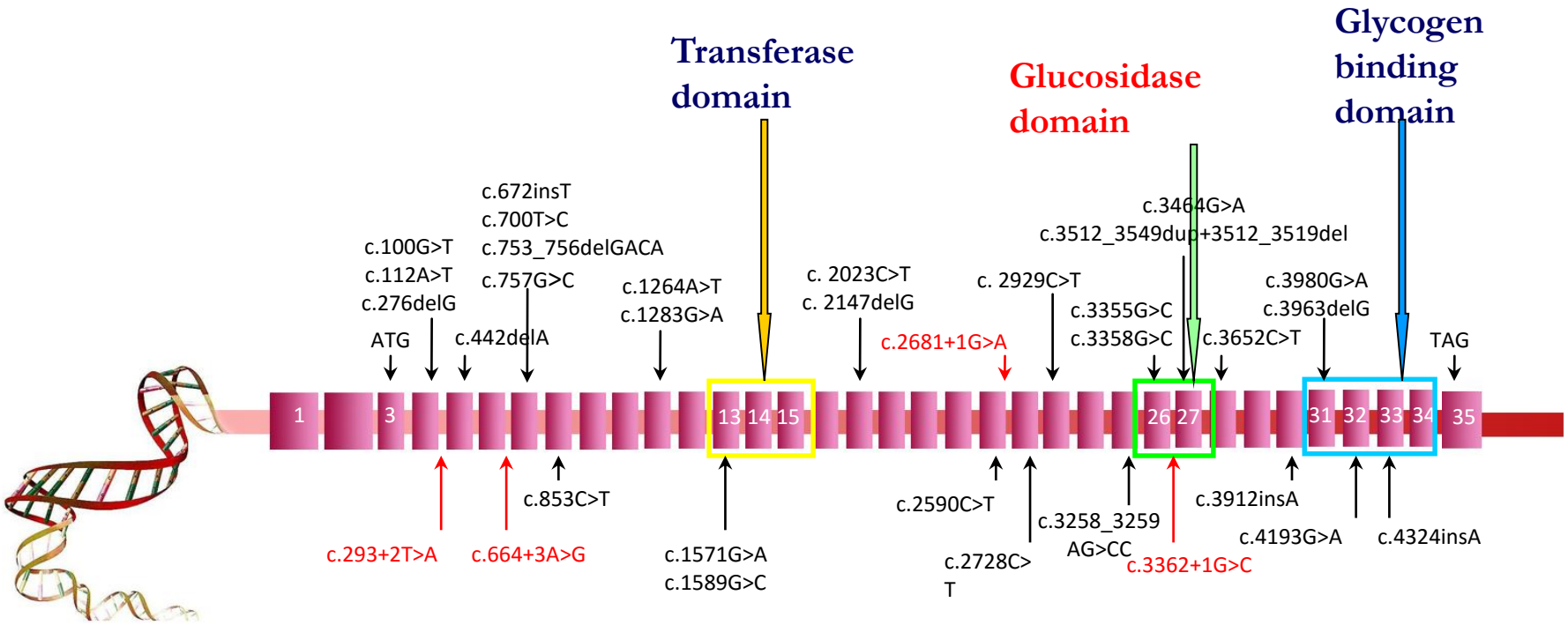

Esame Istologico di muscolo scheletrico di un paziente affetto da GSDIII

TG

PAS

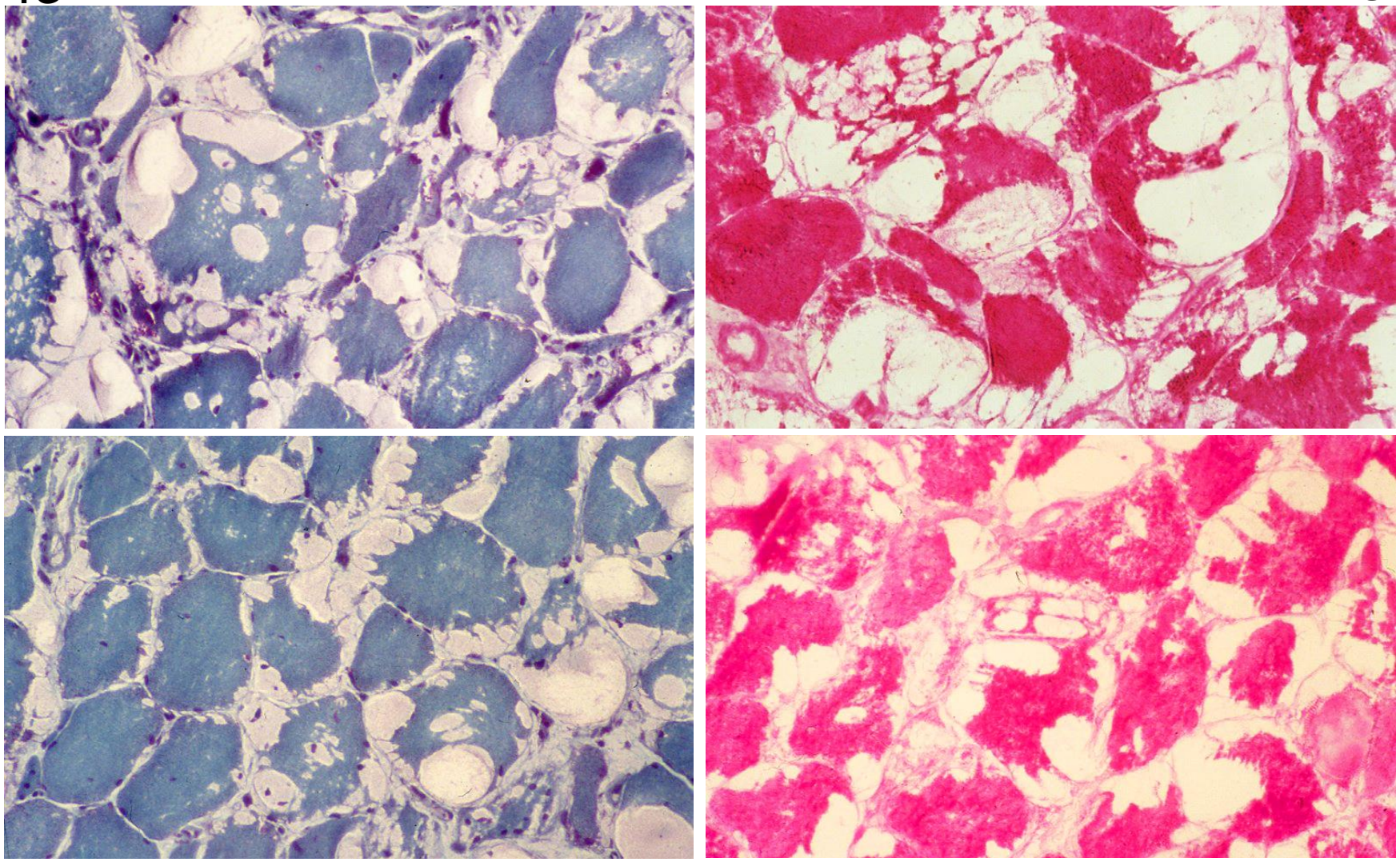

40X

Esame Ultrastrutturale di muscolo scheletrico di un paziente affetto da GSDIII

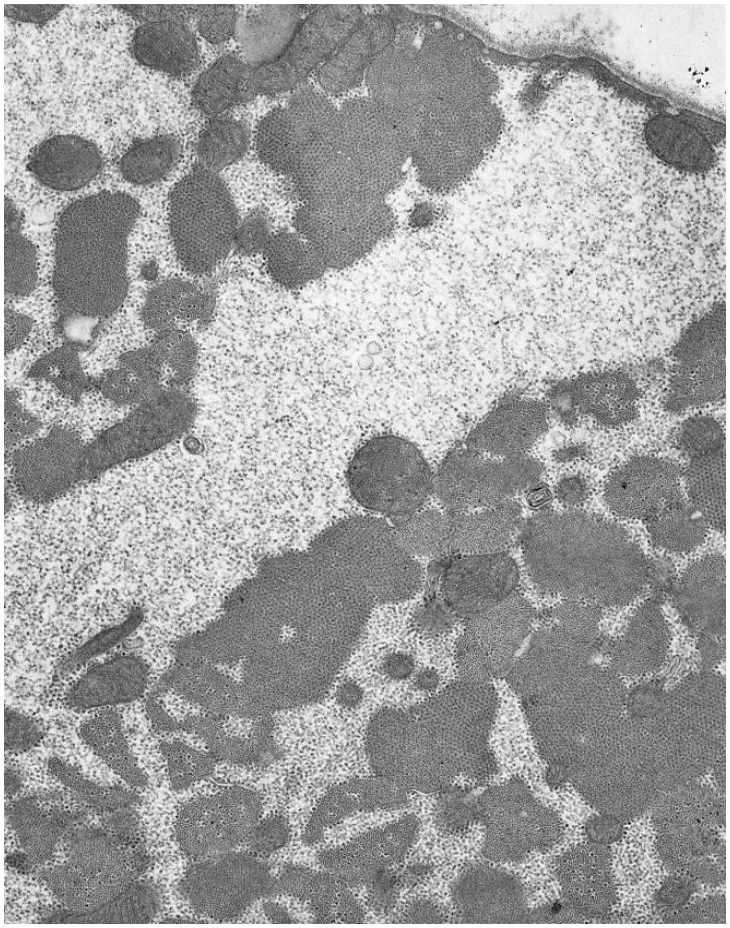

12000X

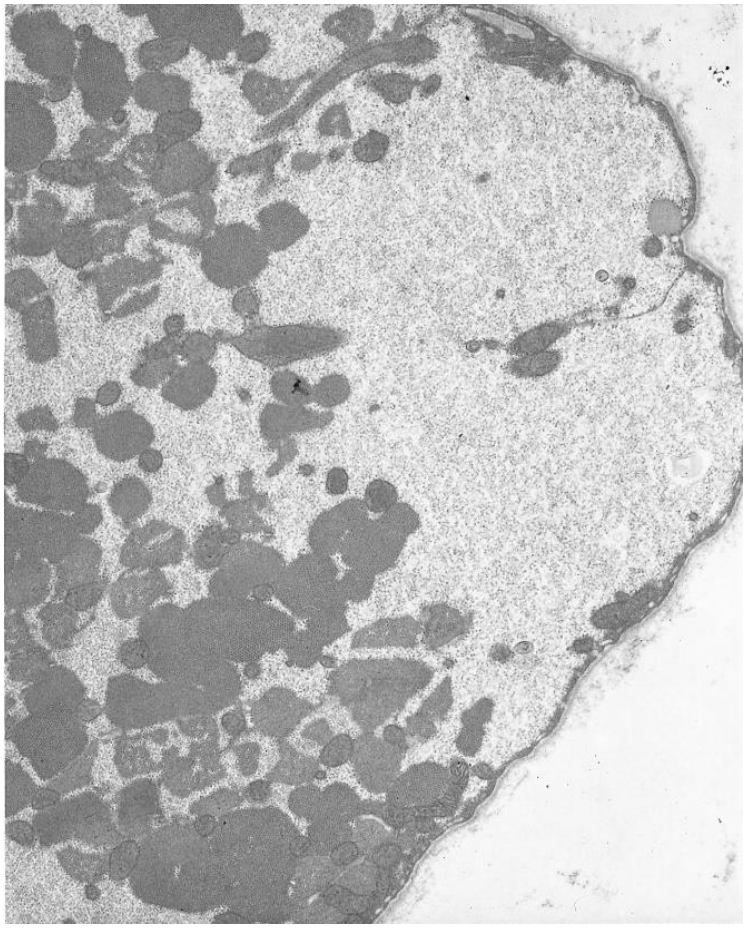

7000X

Glicogenosi in animali domestici (cani e gatti)

J Inherit Metab Dis

Table 1 GSD in cats and dogs

Disorder	Enzyme defect	Breed	Tissue involvement
Type I; von Gierke	Glucose-6-phosphatase	Maltese terrier	Liver, kidney
Type II; Pompe	Acid α-glucosidase	Lapphund dog	Heart, skeletal muscle
Type IIIa; Cori	Glycogen debranching	Curly-coated retriever	Liver, skeletal muscle
Type IV; Andersen	Glycogen branching	Norwegian forest cat	Skeletal muscle, neurons
Type VII; Tarui	Phosphofructokinase	English Springer spaniel	Erythrocytes, skeletal muscle

Brooks & Koeberl J Inherit Metab Dis 2014

Le glicogenosi che colpiscono gli animali da compagnia sono state ben caratterizzate, e aiutano nella comprensione dei meccanismi patologici delle malattie e lo sviluppo di terapie mirate alla loro cura

Modelli Animali nella Ricerca Scientifica

Sono utili perché:

- **sono biologicamente simili agli uomini**
- **possono interagire e reagire a determinati stimoli riproducendo quello che succede nell'uomo**
- **aiutano nella comprensione dei meccanismi patologici di molte malattie e nello sviluppo di terapie.**

Vol 439|23 February 2006|doi:10.1038/nature04422 nature

LETTERS

Facioscapulohumeral muscular dystrophy in mice overexpressing *FRG1*

Davide Gabellini[1], Giuseppe D'Antona[2], Maurizio Moggio[3], Alessandro Prelle[3], Chiara Zecca[3], Raffaella Adami[2], Barbara Angeletti[4]†, Patrizia Ciscato[3], Maria Antonietta Pellegrino[2], Roberto Bottinelli[2], Michael R. Green[1] & Rossella Tupler[1,4]†

Cell PRESS

Cell Metabolism
Article

In Vivo Correction of COX Deficiency by Activation of the AMPK/PGC-1α Axis

Carlo Viscomi,[1,4] Emanuela Bottani,[1,4] Gabriele Civiletto,[1] Raffaele Cerutti,[1] Maurizio Moggio,[2] Gigliola Fagiolari,[2] Eric A. Schon,[3] Costanza Lamperti,[1] and Massimo Zeviani[1,*]

doi:10.1093/brain/awt325 Brain 2014: 137; 57–68 | 57

BRAIN
A JOURNAL OF NEUROLOGY

Pantethine treatment is effective in recovering the disease phenotype induced by ketogenic diet in a pantothenate kinase-associated neurodegeneration mouse model

Dario Brunetti,[1] Sabrina Dusi,[1] Carla Giordano,[2] Costanza Lamperti,[1] Michela Morbin,[3] Valeria Fugnanesi,[3] Silvia Marchet,[1] Gigliola Fagiolari,[4] Ody Sibon,[5] Maurizio Moggio,[4] Giulia d'Amati[2] and Valeria Tiranti[1]

Modelli Animali di Glicogenosi

THE JOURNAL OF BIOLOGICAL CHEMISTRY Vol. 273, No. 30, Issue of July 24, pp. 19086–19092, 1998
Printed in U.S.A.

Targeted Disruption of the Acid α-Glucosidase Gene in Mice Causes an Illness with Critical Features of Both Infantile and Adult Human Glycogen Storage Disease Type II*

(Received for publication, February 25, 1998, and in revised form, May 7, 1998)

Nina Raben‡§, Kanneboyina Nagaraju‡, Eunice Lee‡, Paul Kessler¶, Barry Byrne‖, Laura Lee‡, Mary LaMarca, Christina King**, Jerrold Ward‡‡, Brian Sauer§§, and Paul Plotz‡**

Human Molecular Genetics, 2011, Vol. 20, No. 22 ***4430–4439***
doi:10.1093/hmg/ddr371
Advance Access published on August 19, 2011

Generation of a novel mouse model that recapitulates early and adult onset glycogenosis type IV

H. Orhan Akman[1,*], Tatiana Sheiko[1], Stacey K.H. Tay[4], Milton J. Finegold[2], Salvatore DiMauro[5] and William J. Craigen[1,3]

J Physiol 593.12 (2015) pp 2693–2706

Phenotype consequences of myophosphorylase dysfunction: insights from the McArdle mouse model

Astrid Brull[1,2], Noemí de Luna[1,2], Albert Blanco-Grau[1], Alejandro Lucia[3,4], Miguel Angel Martin[4], Joaquin Arenas[4], Ramon Martí[1,2], Antoni L Andreu[1,2] and Tomàs Pinós[1,2]

Vettore di Clonaggio per la generazione di un topo Agl knock out

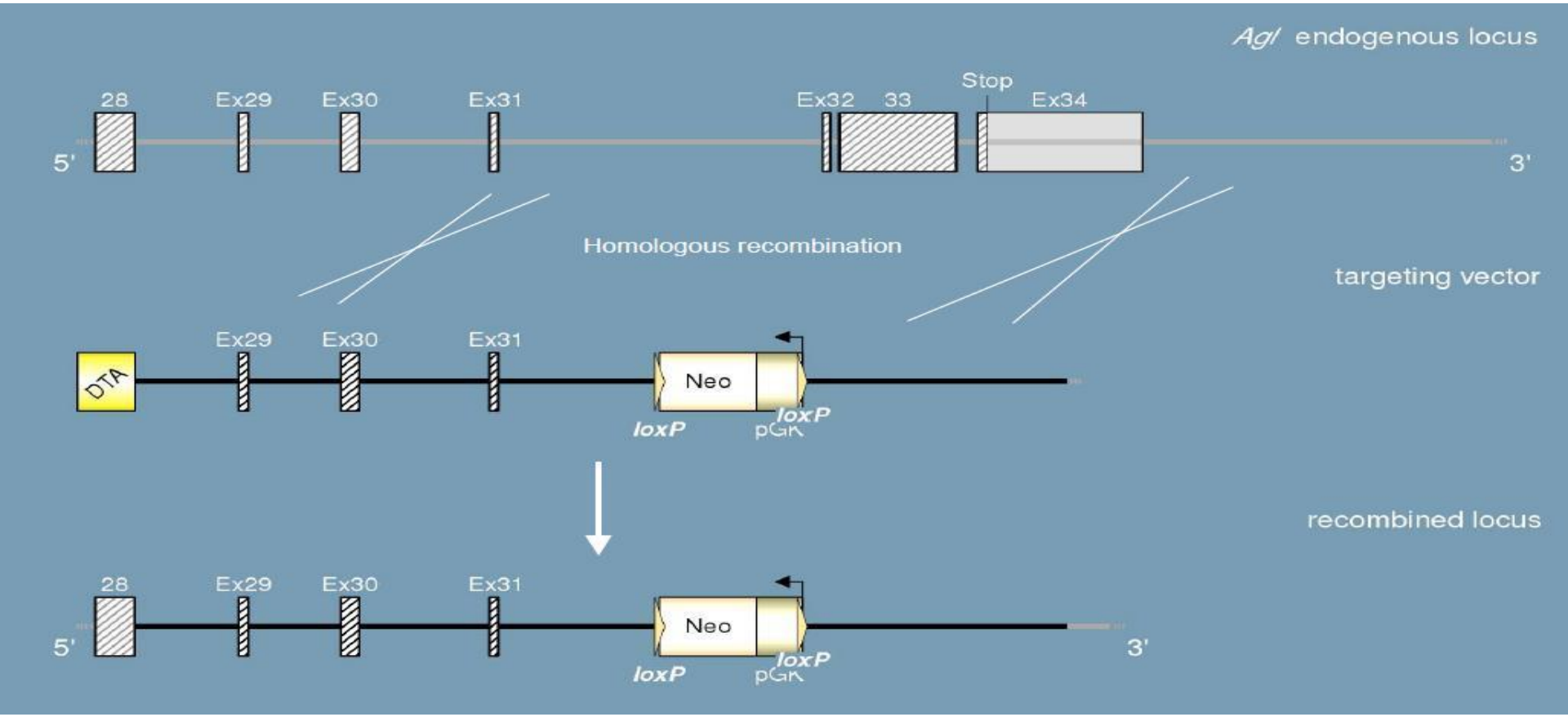



Topo KO di 18 mesi

Analisi Western blot

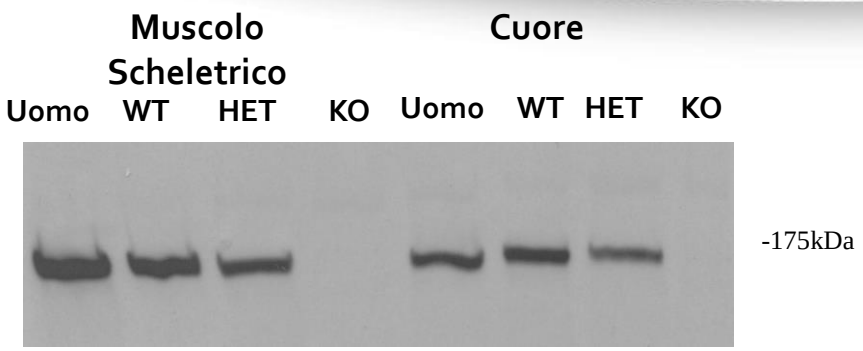

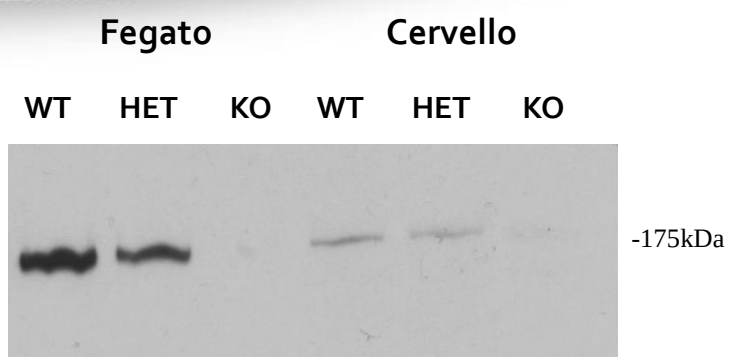

Attività Enzimatica

GDE activity pmole glucose/min/mg protein			
	+/+	+/–	–/–
Muscle	216.25±36.40	134.23±13.51	2.30±1.25
Liver	37.23±1.45	23.37±6.34	5.58±1.65

Gli animali KO sono vitali e non differiscono in dimensioni e peso dai loro fratelli WT ed eterozigoti sia alla nascita sia durante la crescita

Età: 4 giorni

Wild Type -

Heterozygote -

Knockout -

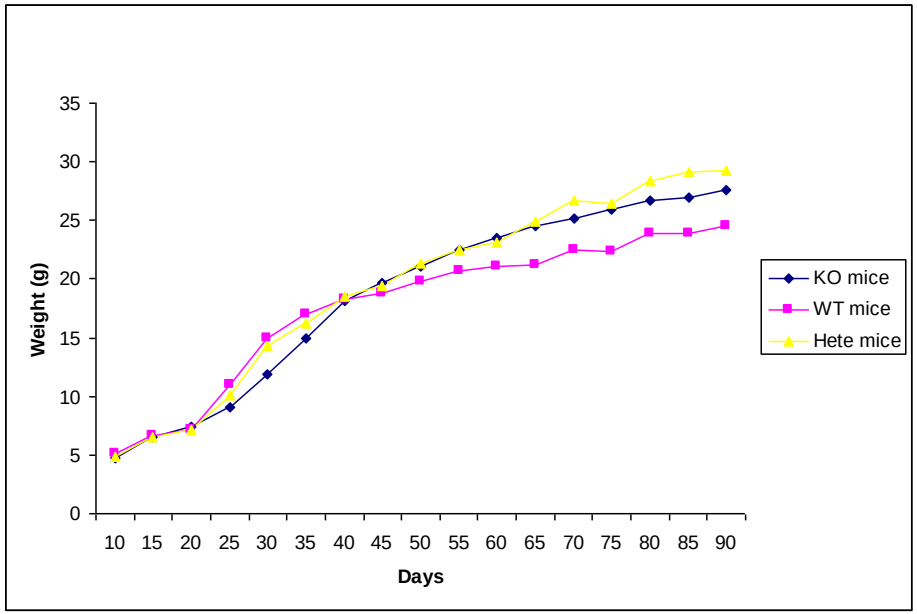

Kaplan-Meier survival plot

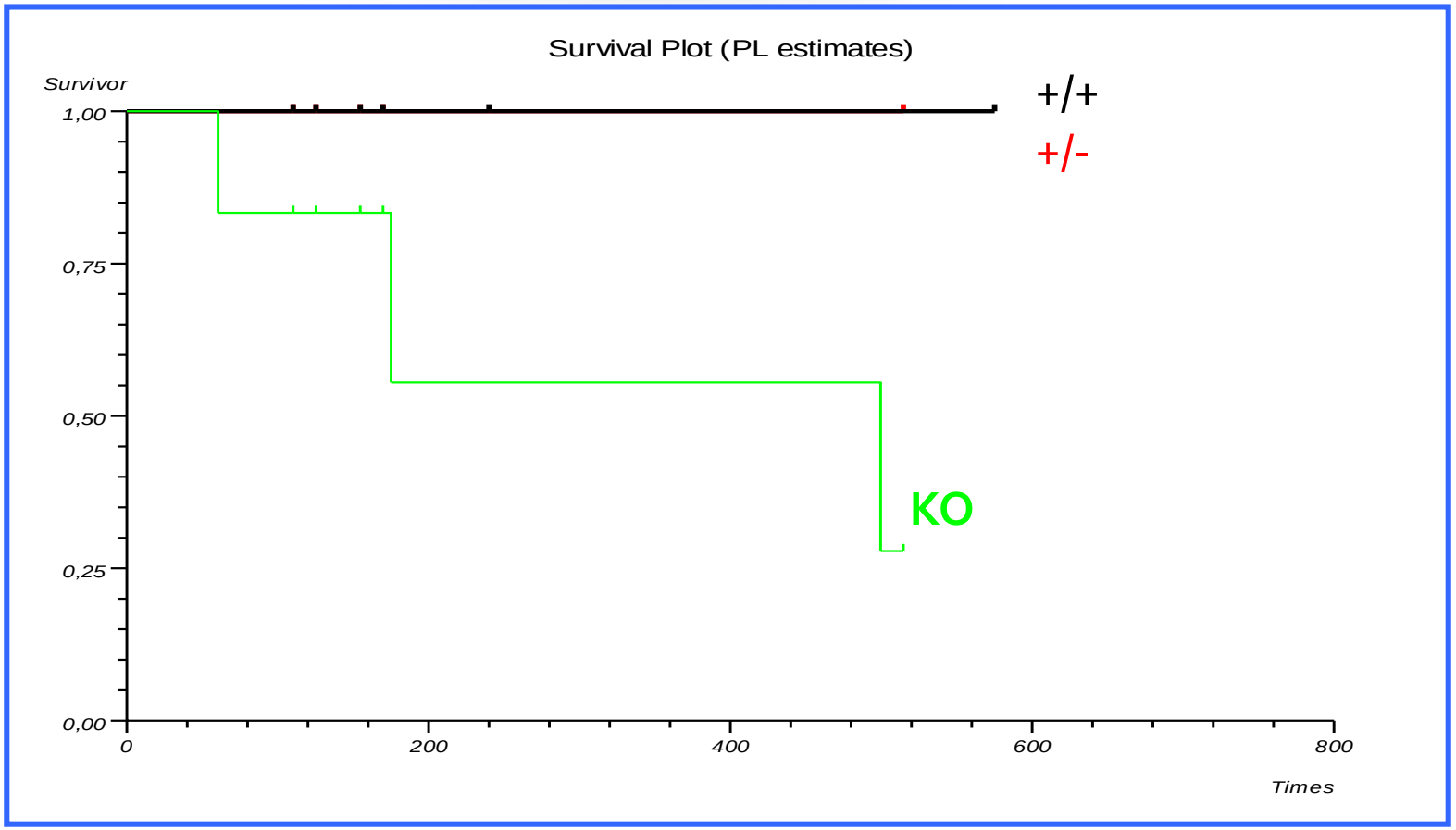

N = 10 per ciascun genotipo

Valutazione funzionale: hind print test

I topi KO, a tutte le età, mostrano difetti dell'andatura dovuti all'estroflessione delle zampe.

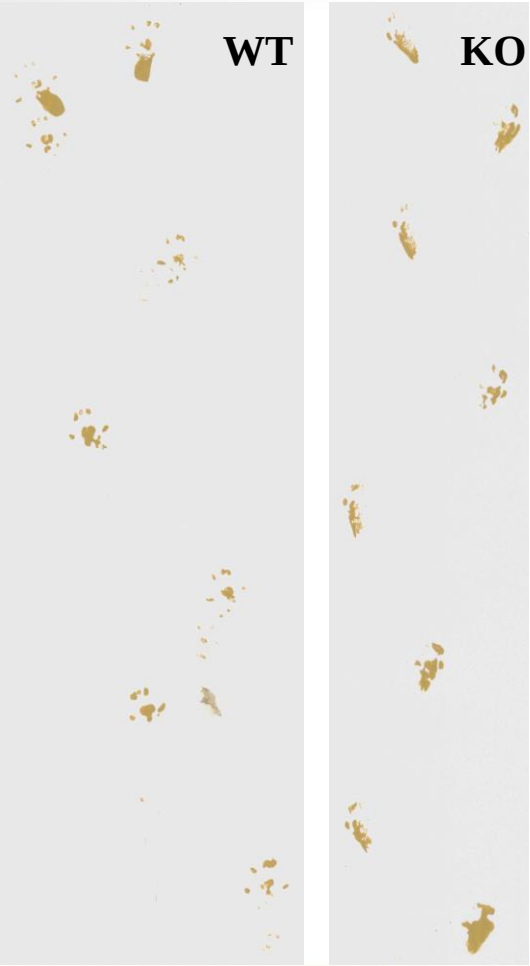

3 mo

Valutazione funzionale: treadmill

Run test

30cm/s

5 min

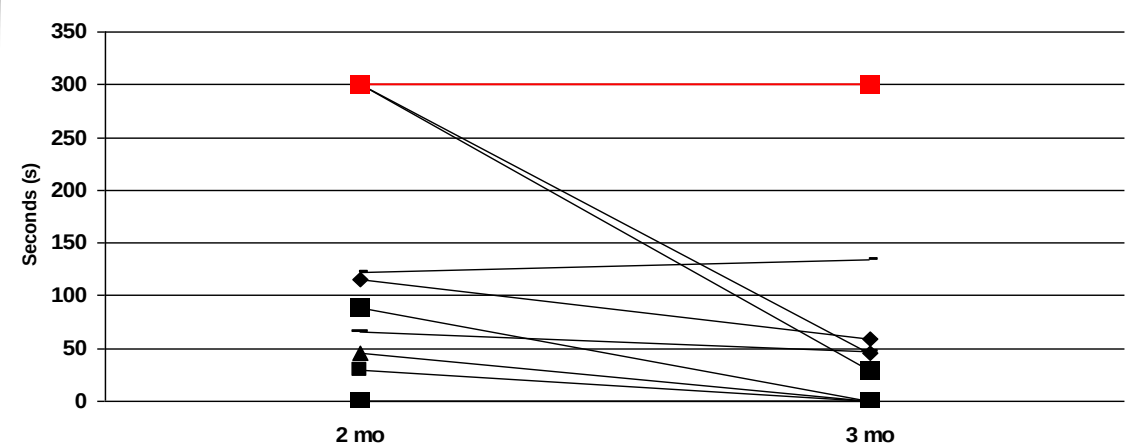

Long walk

15cm/s

350 m

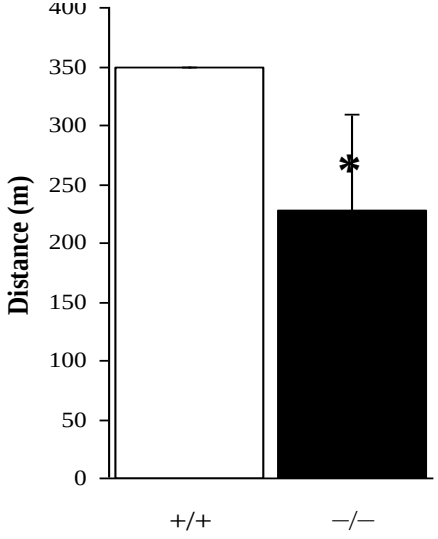

9 mo

Valutazione funzionale: Rotarod

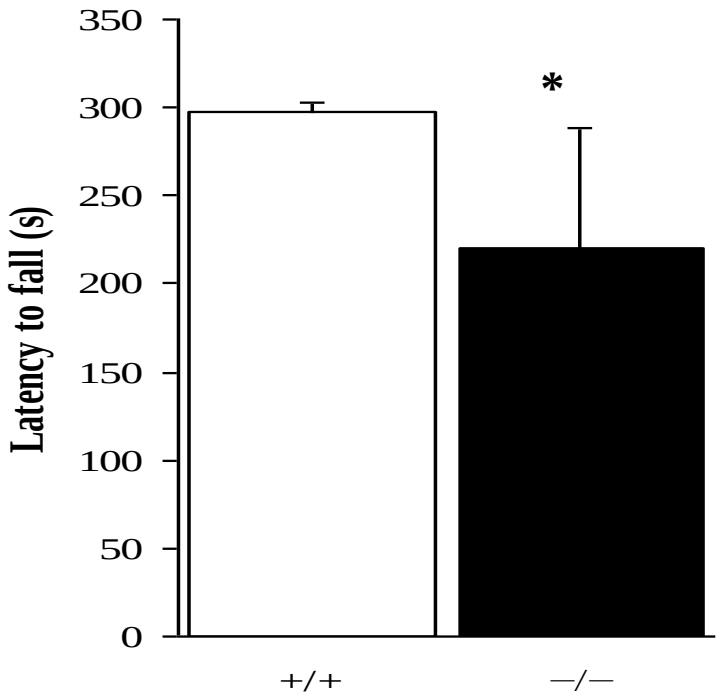

9 mo

Glicemia

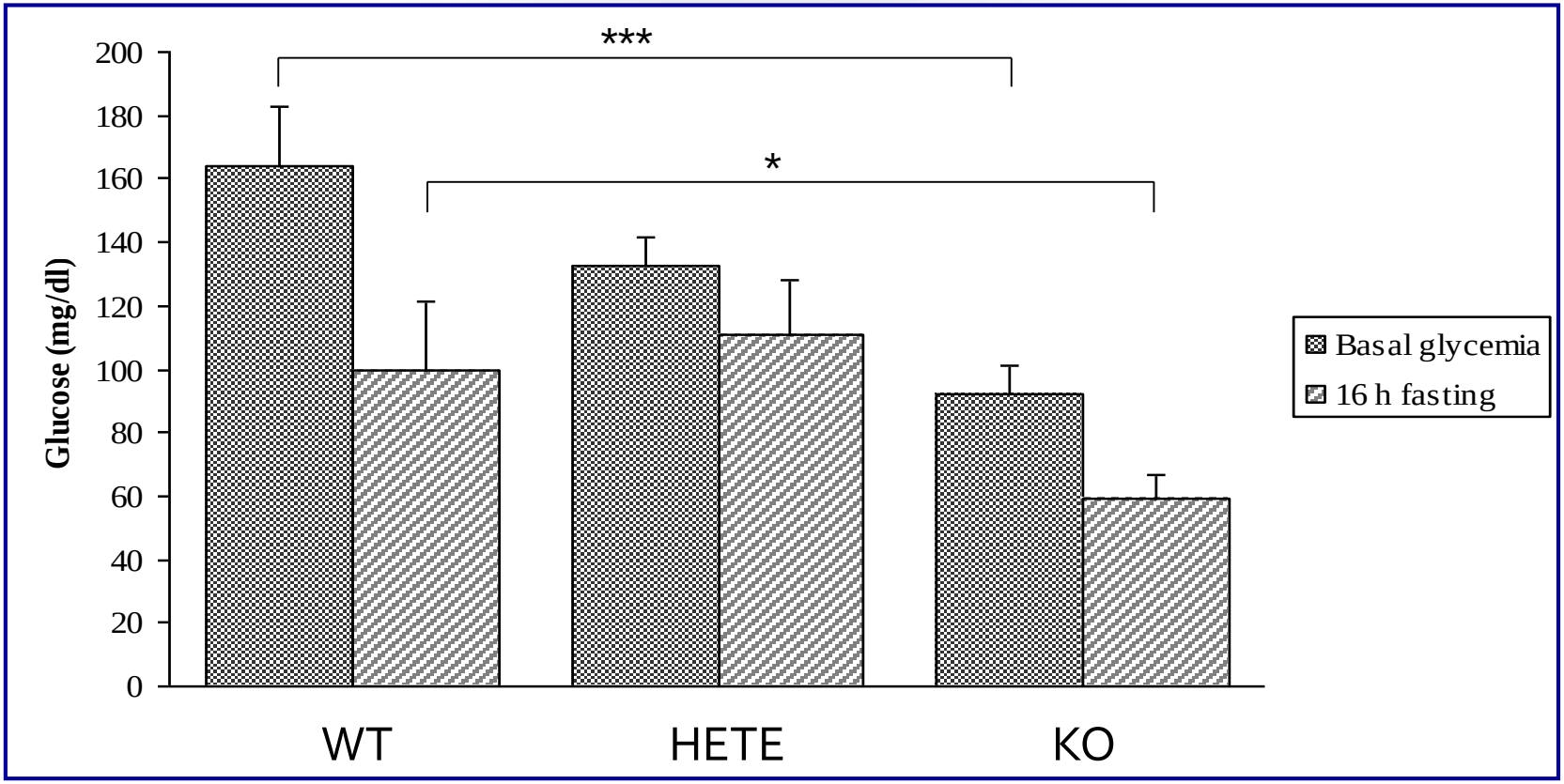

*** P<0.0001

* P<0.05

Analisi biochimiche

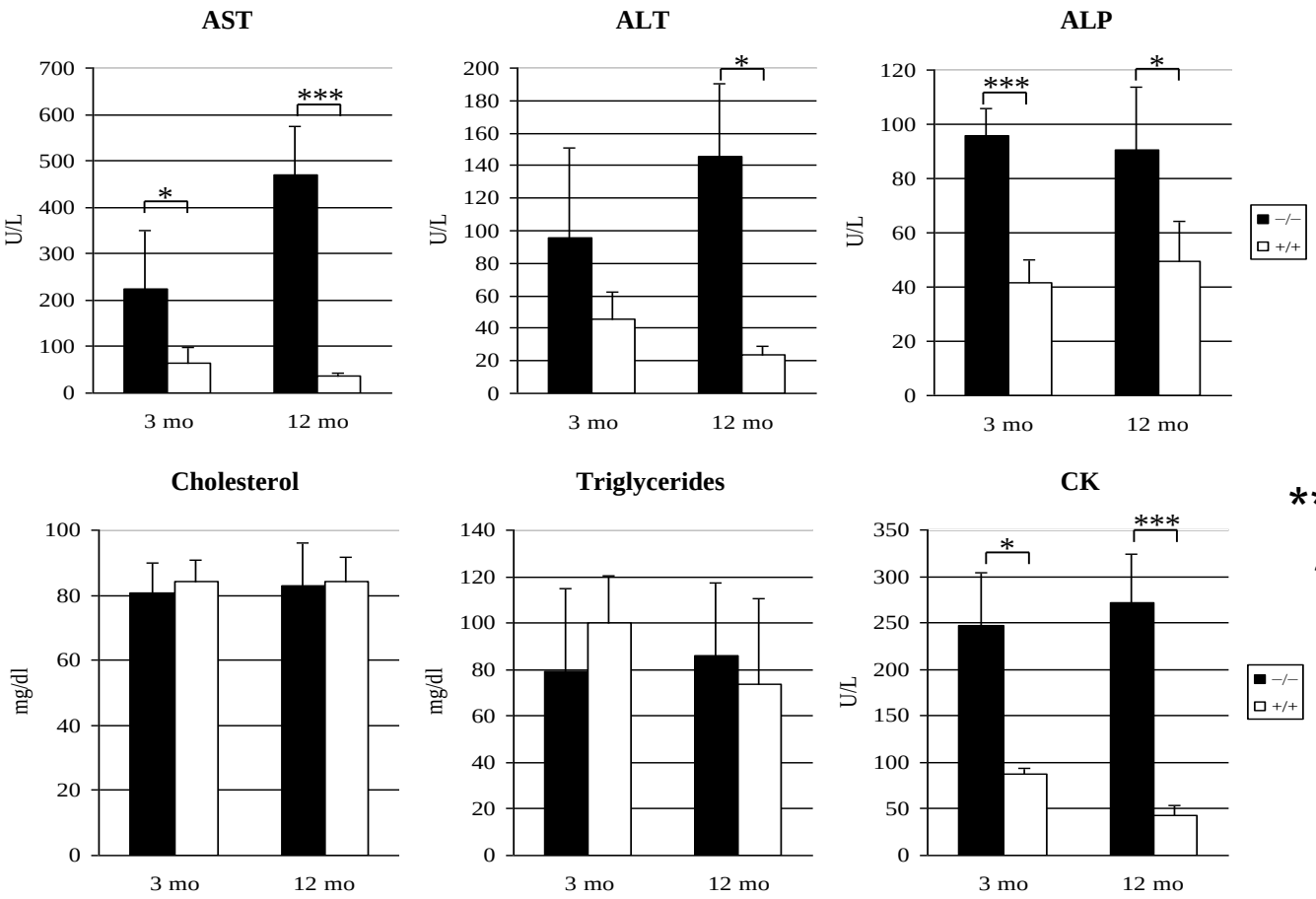

*** P<0,005

* P<0.05

Il fegato del topo KO rispetto al WT è di dimensioni maggiori e di colore rosso scuro

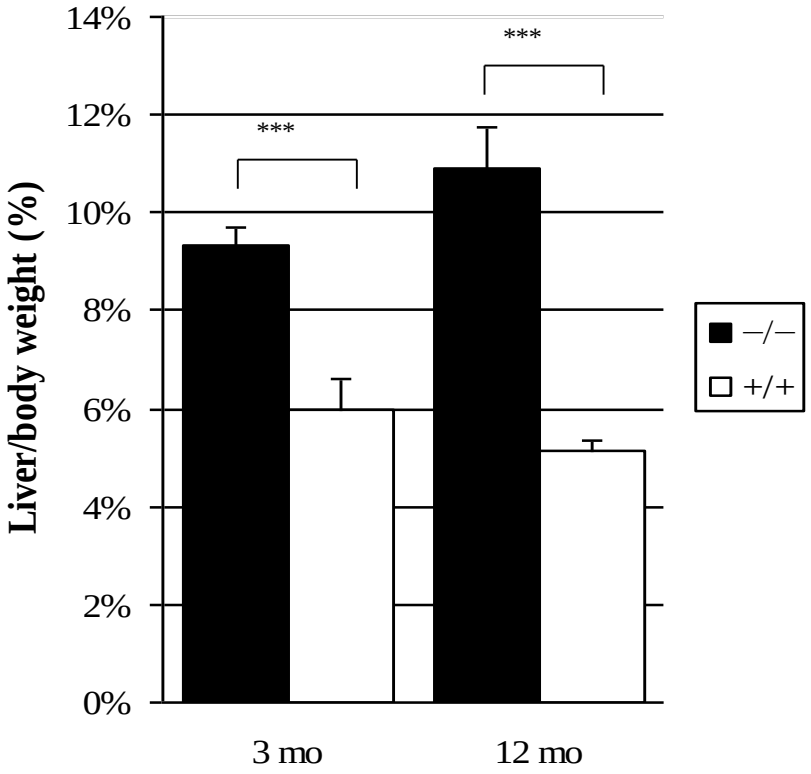

KO WT

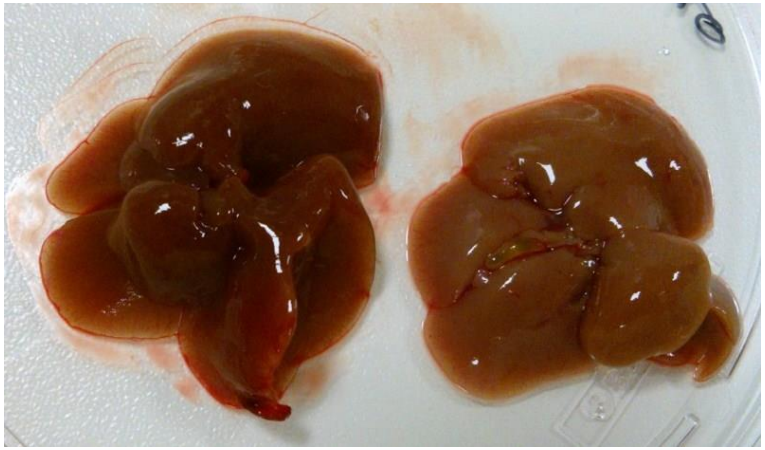

Non vi sono segni di cirrosi o adenomi

Contenuto in glicogeno

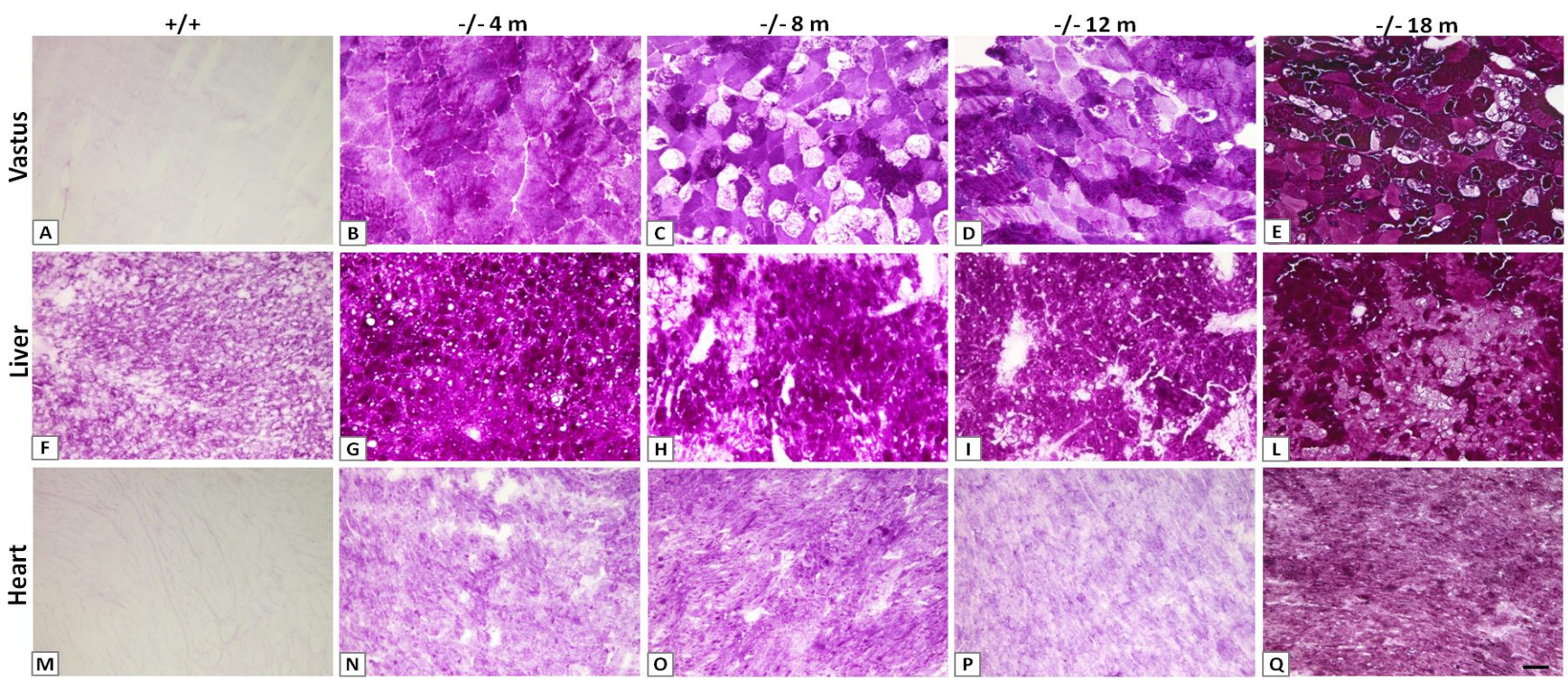

4 mo 8 mo 12 mo 18 mo

Colorazione PAS

Fegato: epatociti gonfi e allargati

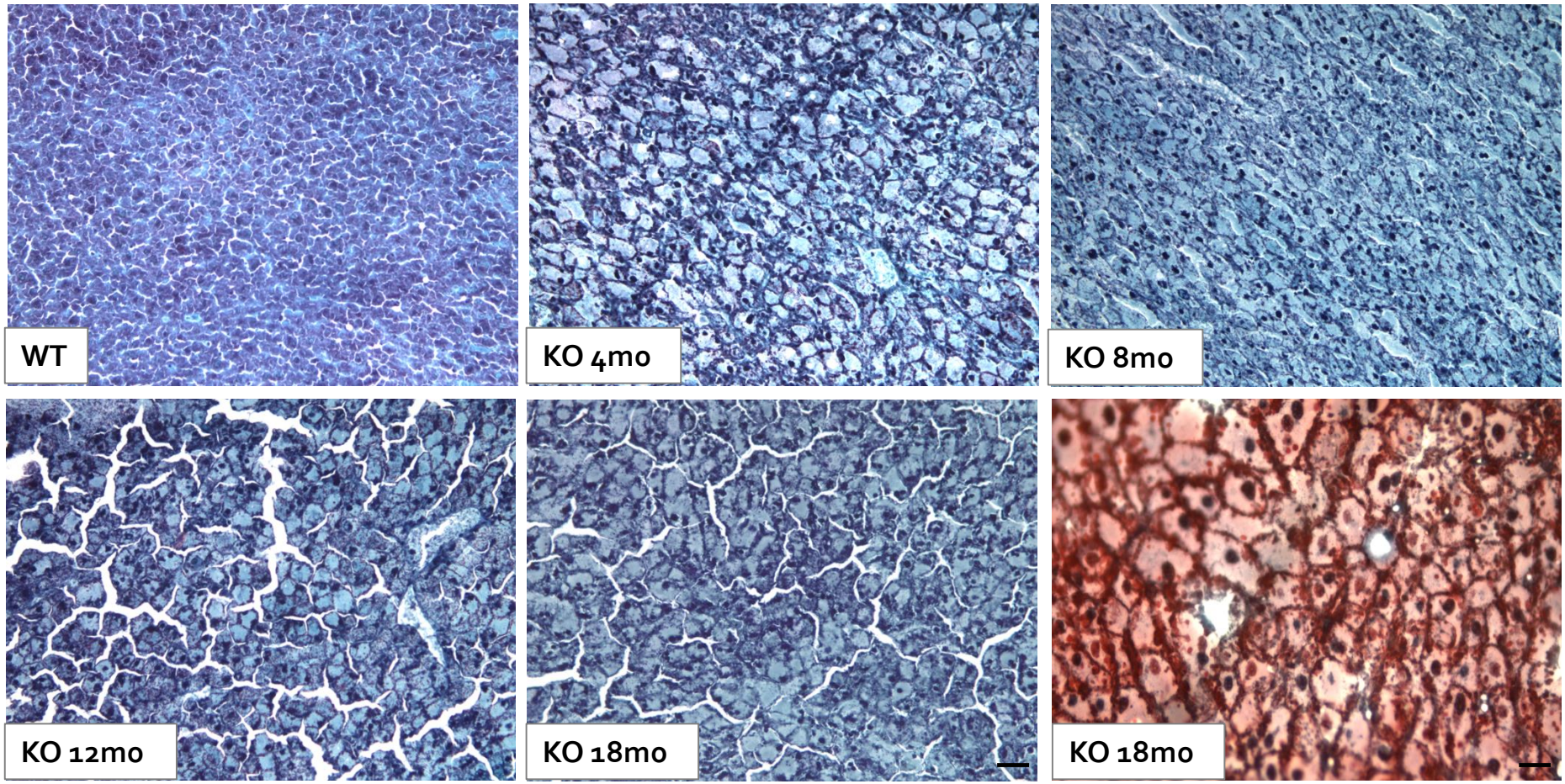

A,B,C,D,E: Colorazione Tricromica di Gomori

F: Colorazione di Masson

Scale bar: — 25 µm

Muscolo scheletrico: progressiva vacuolizzazione

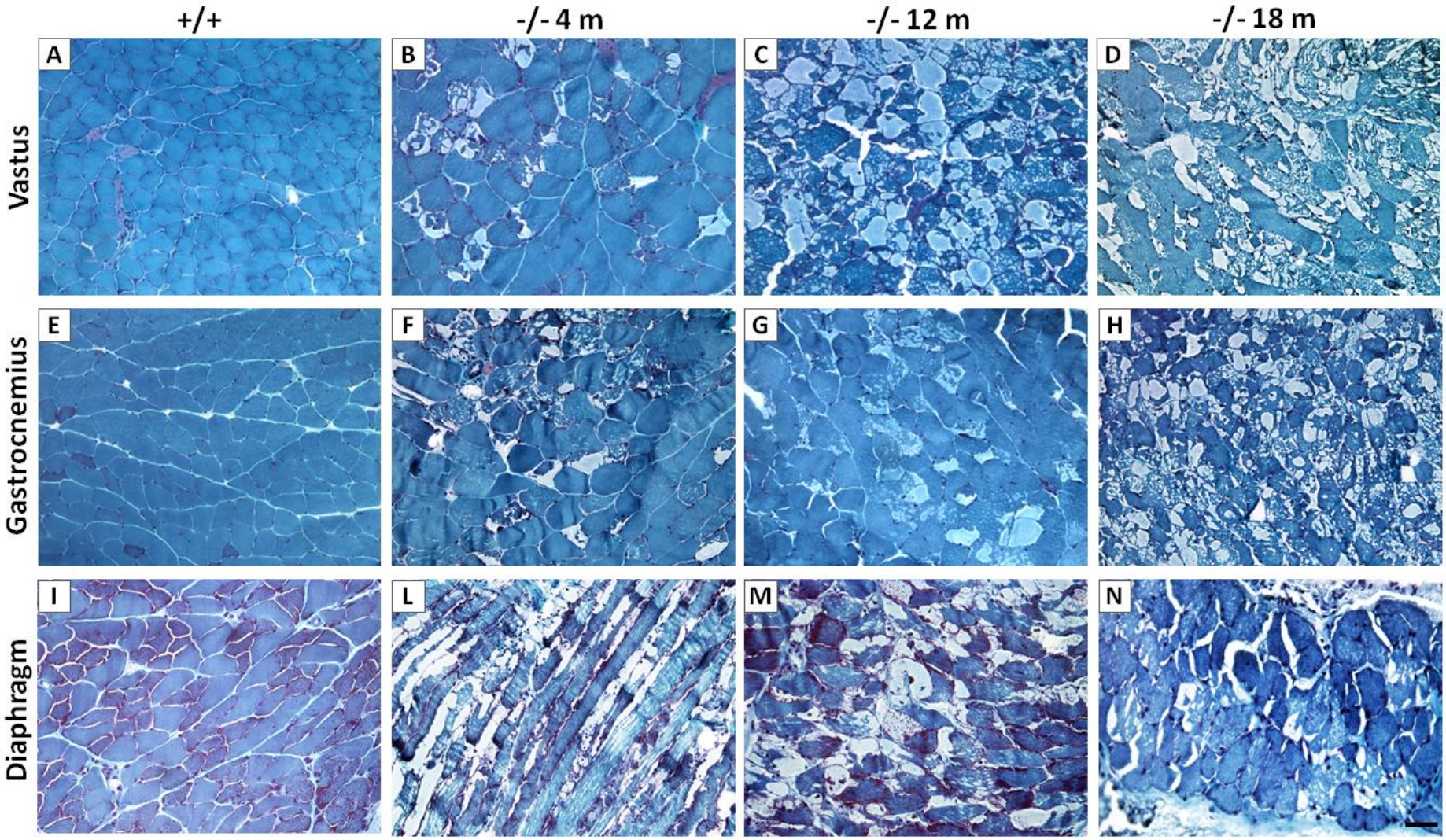

Scale bar: — 20 µm

ANALISI ULTRASTRUTTURALE: muscolo scheletrico



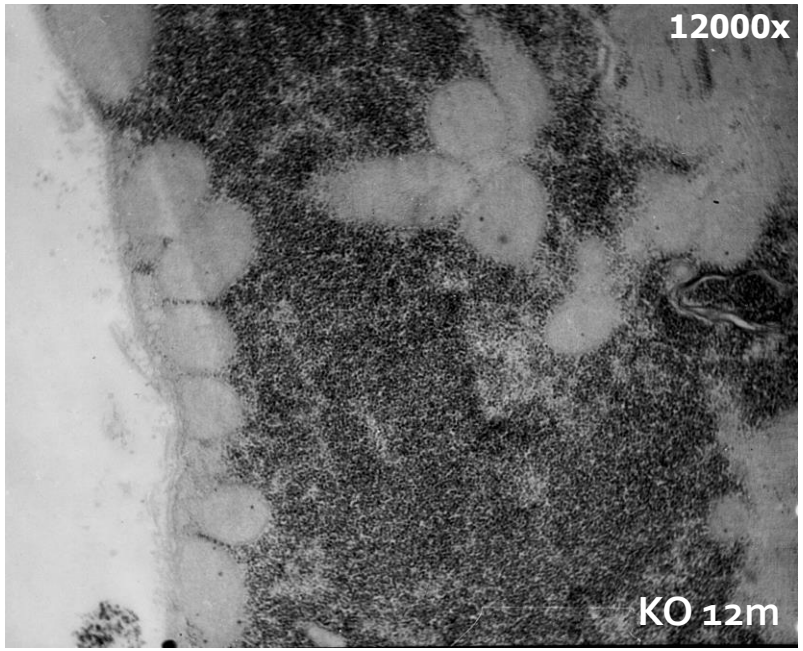





Contenuto in glicogeno

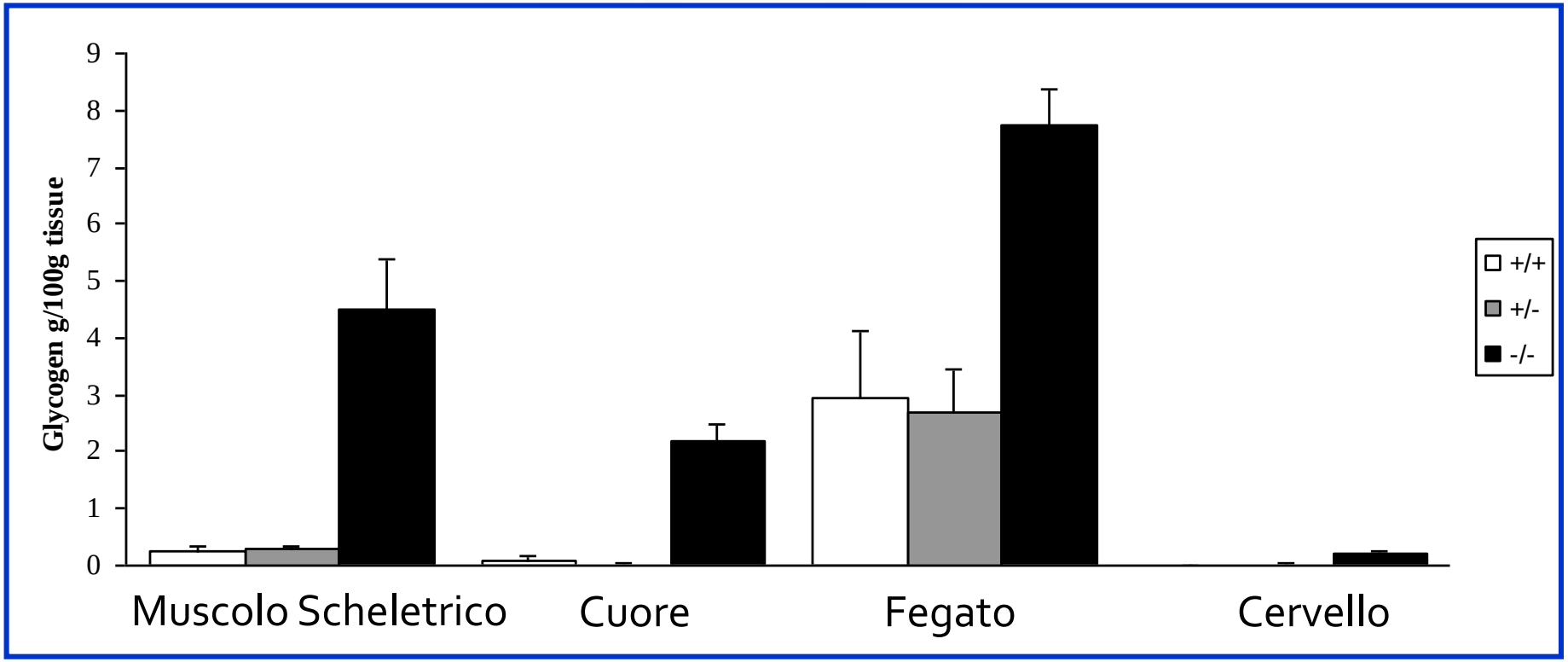

N=5 per ciascun gruppo

P <0.0005

Lingua: importante vacuolizzazione

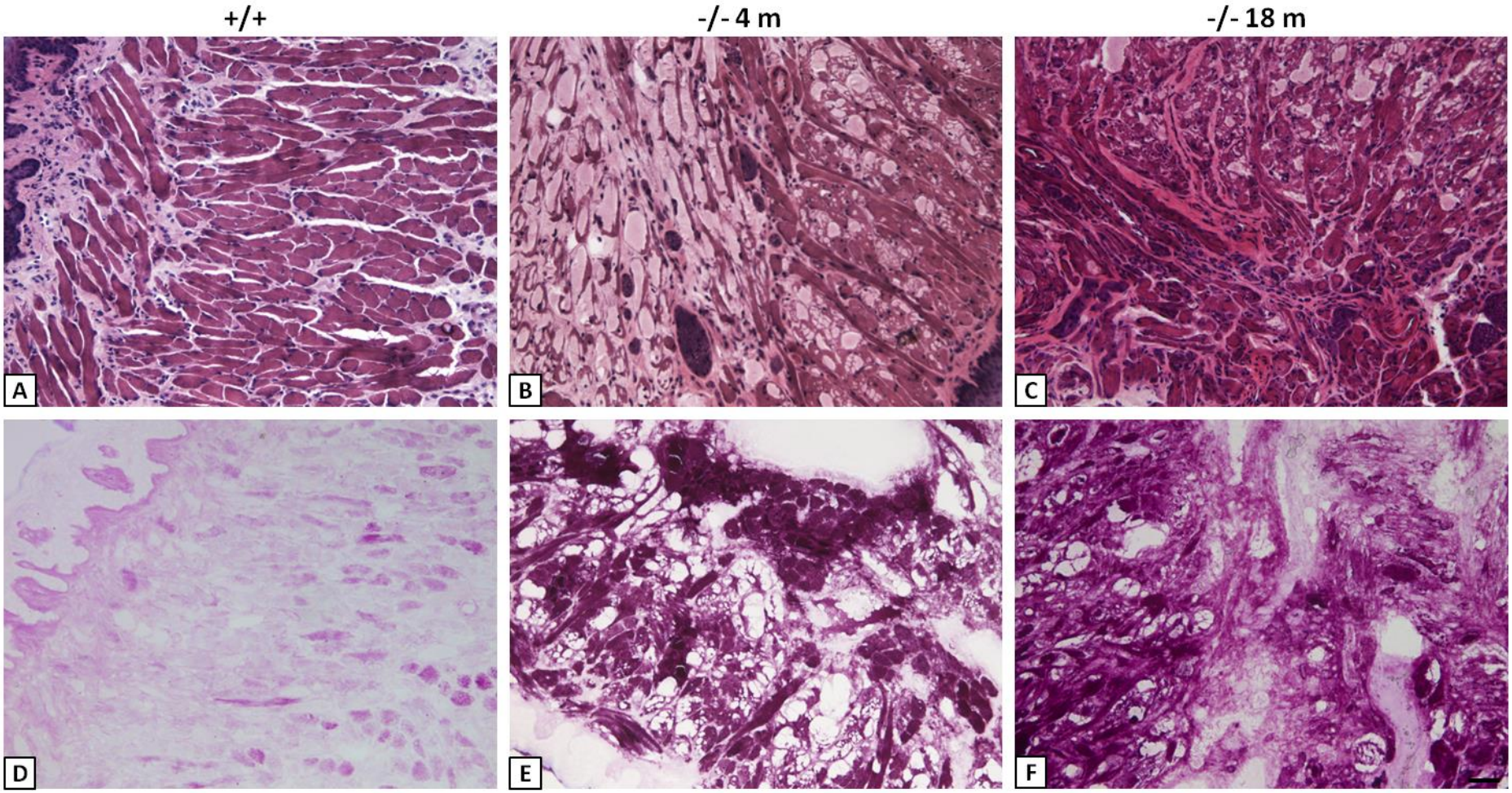

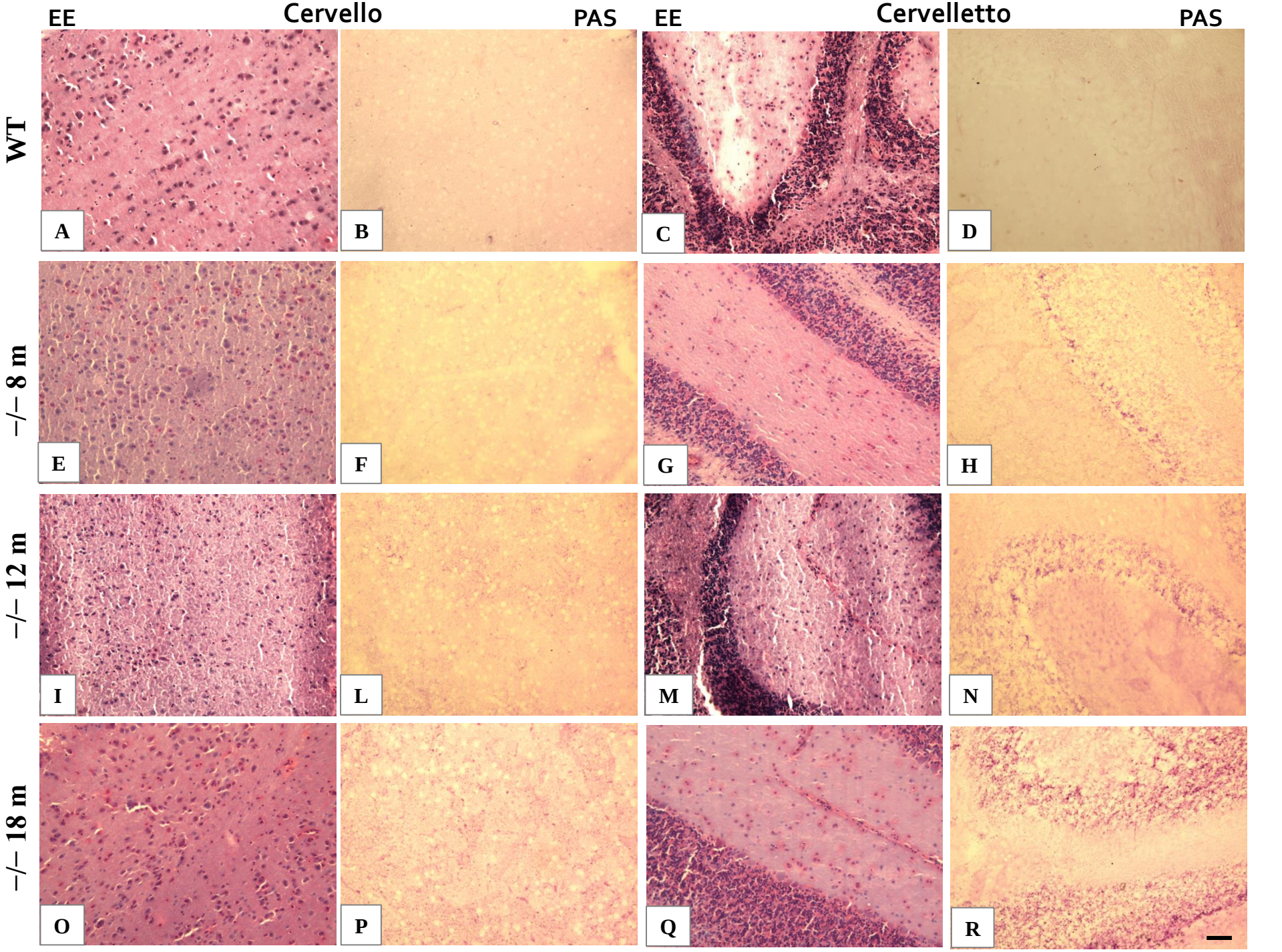
EE
Cervello
PAS
EE
Cervelletto
PAS
WT
−/− 8 m
−/− 12 m
−/− 18 m
A
B
C
D
E
F
G
H
I
L
M
N
O
P
Q
R

Nervo sciatico: morfologia normale

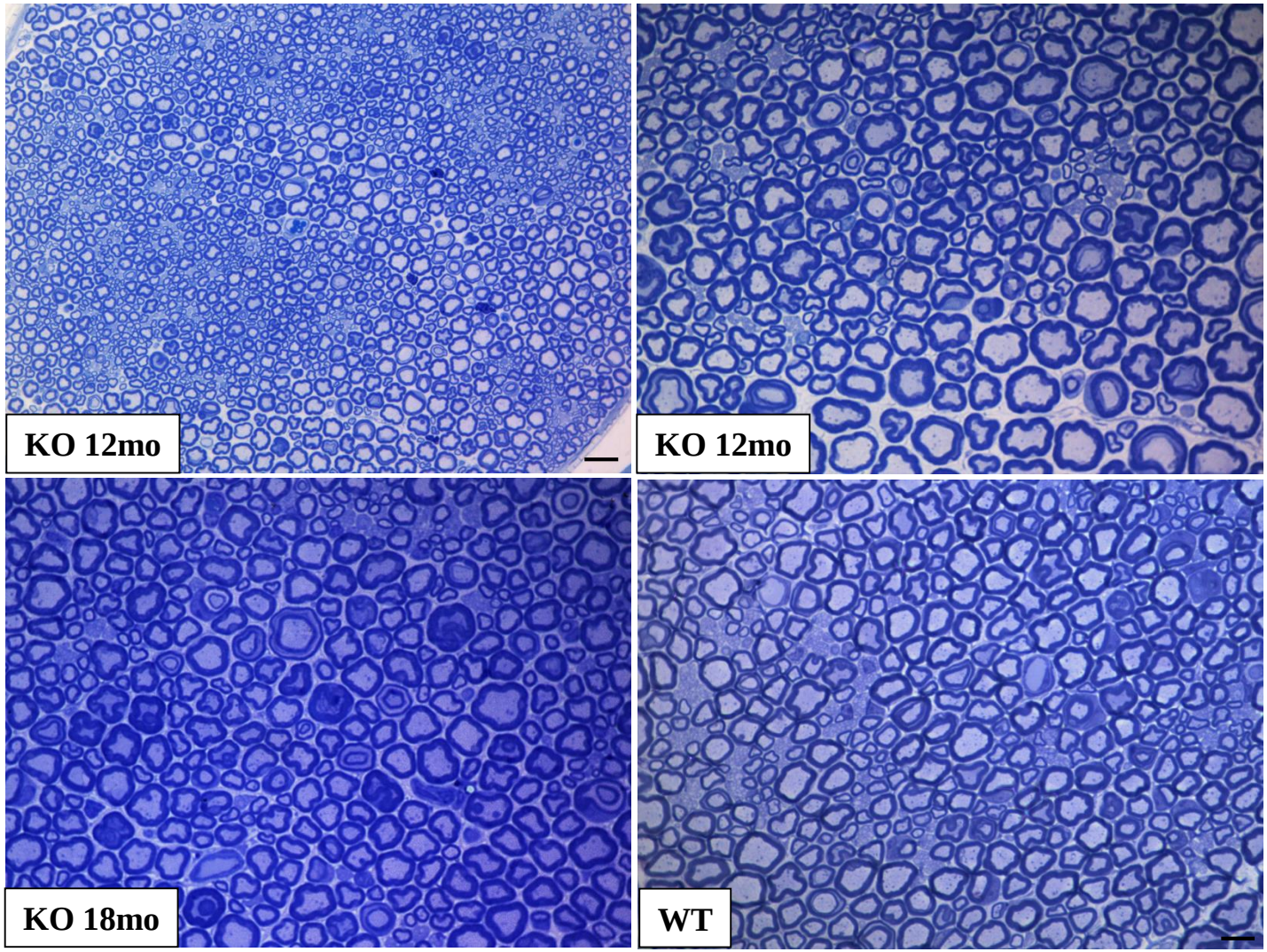

Colorazione Blu di Toluidina

Scale bar: — 12.5 µm

Conclusioni

- Abbiamo studiato un topo KO per il gene AGL. L'enzima deramificante GDE e la sua attività sono completamente assenti in tutti i tessuti
- I topi KO mostrano un'alterata funzione muscolare fin dalla giovane età
- Nel topo KO le transaminasi epatiche e le CK sono aumentate
- Le analisi istologiche hanno rivelato alterazioni nel muscolo scheletrico che peggiorano progressivamente con l'età.
- I topi KO presentano epatomegalia
- Il fegato, il muscolo scheletrico e il cuore mostrano un aumento del contenuto in glicogeno

Conclusioni

Il nostro modello murino AGL KO riproduce perfettamente la GSDIII umana

UOMO

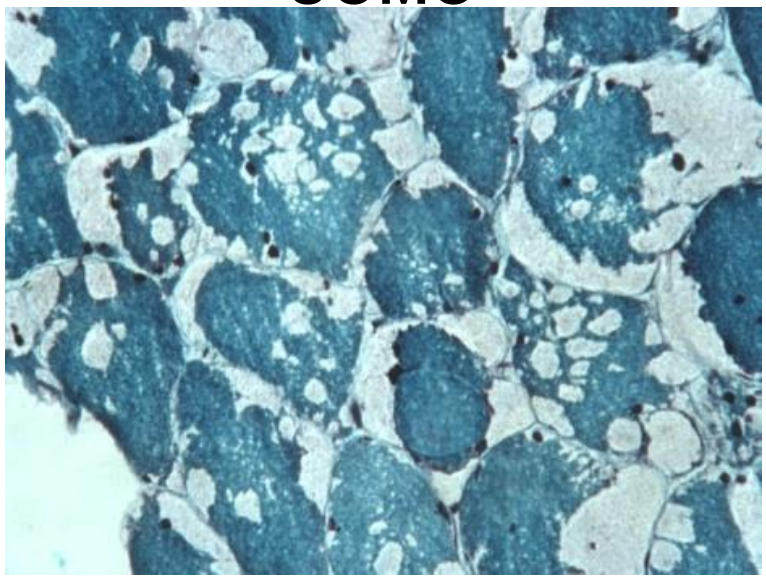

TOPO KO

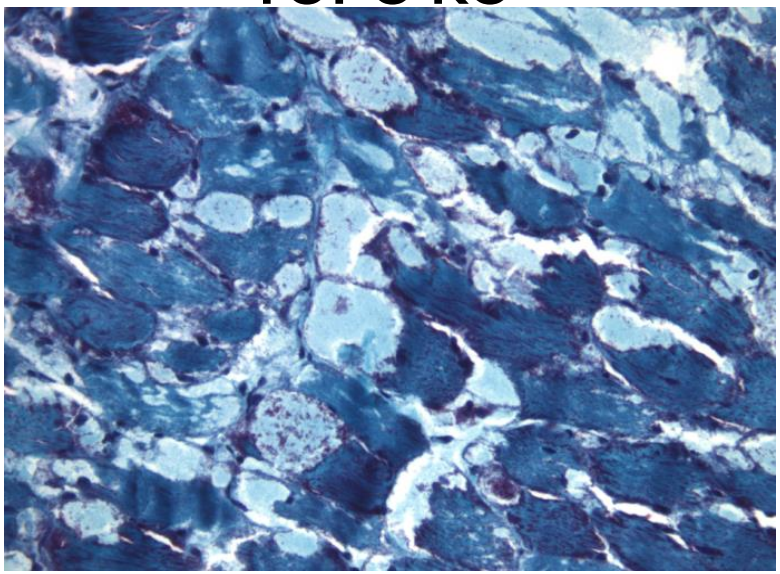

Biochimica et Biophysica Acta 1842 (2014) 2318–2328

Contents lists available at ScienceDirect

Biochimica et Biophysica Acta

journal homepage: www.elsevier.com/locate/bbadis

Glycogen storage disease type III: A novel *Agl* knockout mouse model

Serena Pagliarani [a,1], Sabrina Lucchiari [a,1], Gianna Ulzi [a], Raffaella Violano [b], Michela Ripolone [b], Andreina Bordoni [a], Monica Nizzardo [a], Stefano Gatti [c], Stefania Corti [a], Maurizio Moggio [b], Nereo Bresolin [a], Giacomo P. Comi [a,*]

[a] *Dino Ferrari Center, Neuroscience Section, Department of Pathophysiology and Transplantation (DEPT), University of Milan, Neurology Unit, IRCCS Foundation Ca' Granda Ospedale Maggiore Policlinico, Milan, Italy*
[b] *Neuromuscular Unit — Fondazione I.R.C.C.S. Ca' Granda, Ospedale Maggiore Policlinico, Milano, Dino Ferrari Centre, University of Milan, Italy*
[c] *Center for Surgical Research, Fondazione IRCCS Ca' Granda, Ospedale Maggiore Policlinico, Milan, Italy*

Prospettive future

Dieta altamente proteica

Terapia genica con Virus Adeno Associati

MUSCOLO Valutazioni PRE- e POST-DIETA HIGH PROTEIN

	VASTO	SOLEO-GASTROCNEMIO	TIBIALE
NT	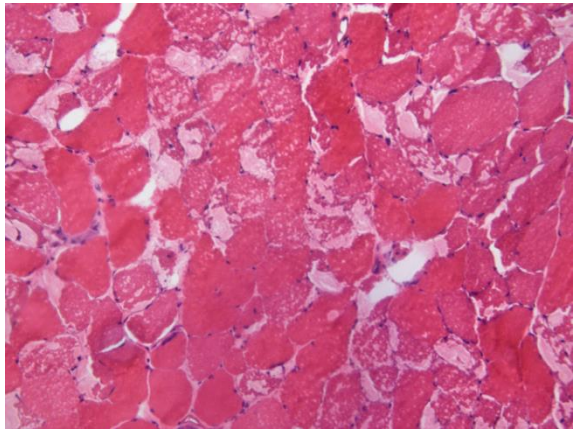	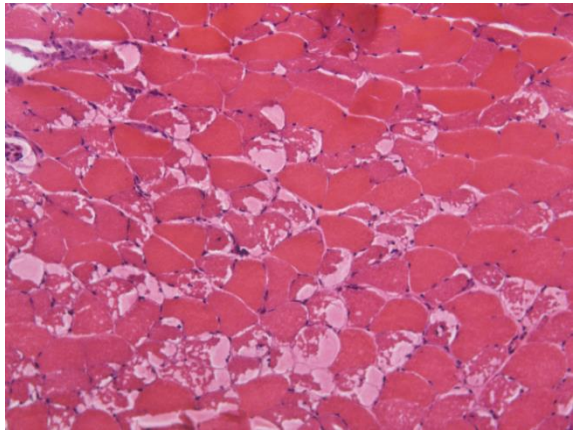	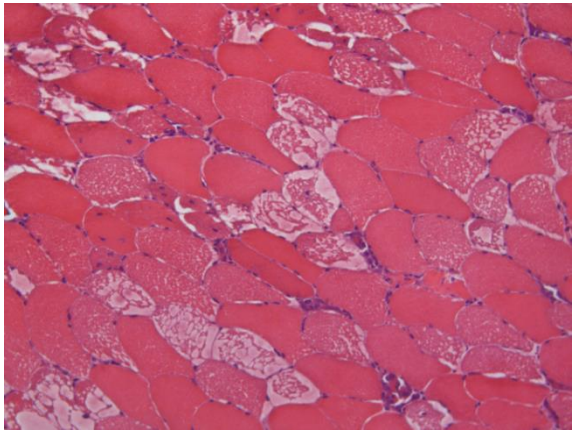
DIETA HP	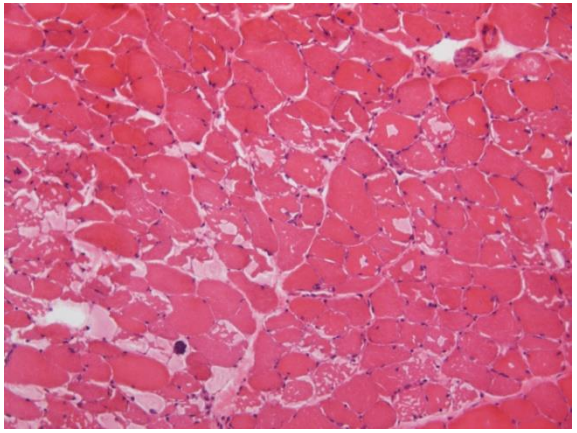	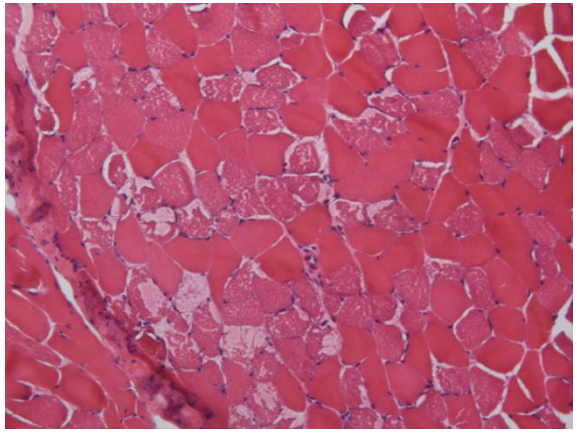	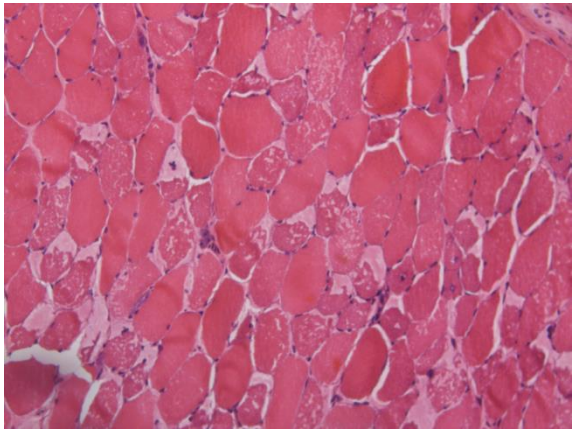

EE 20X

FEGATO

Valutazioni PRE- e POST-DIETA HIGH PROTEIN

WT

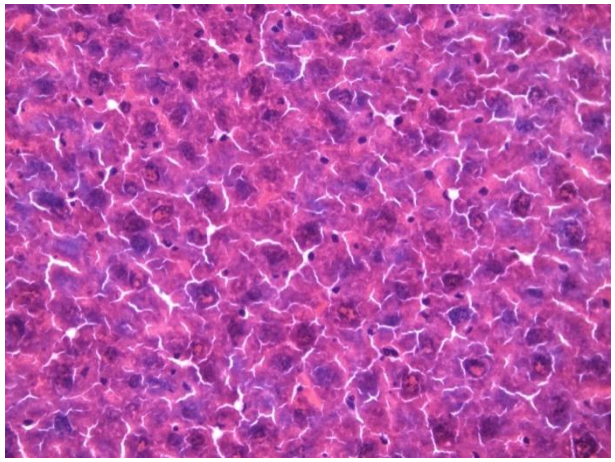

KO NON TRATTATO

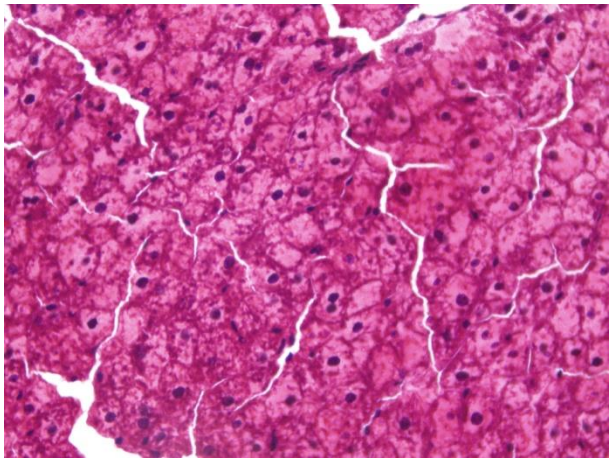

DIETA HIGH PROTEIN

KO 2 MESI

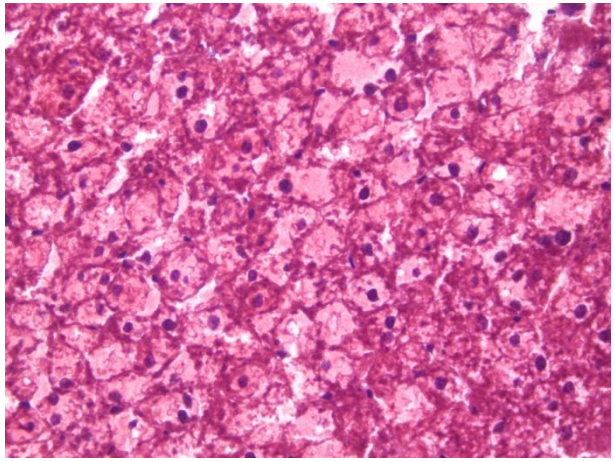

KO 3 MESI

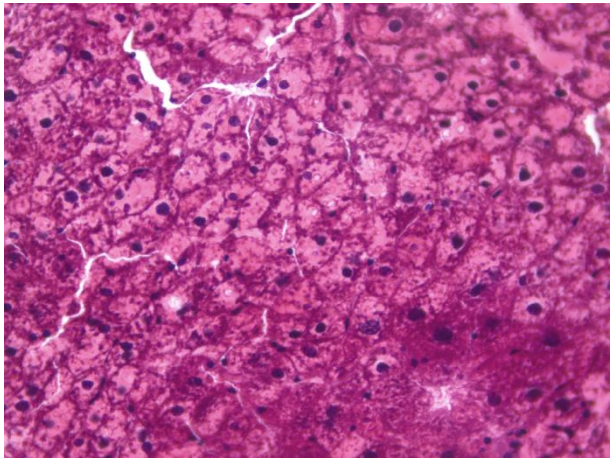

KO 4 MESI

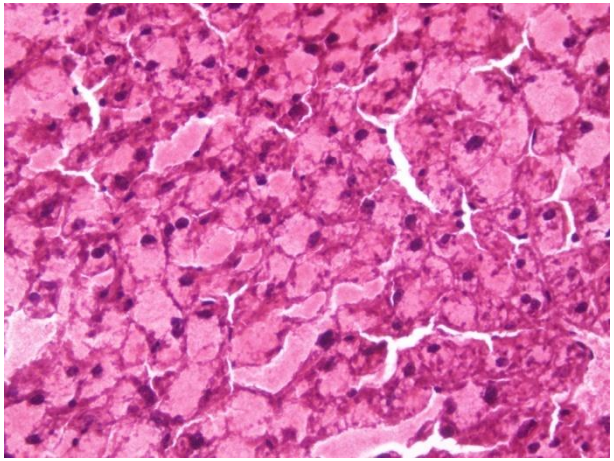

EE 40X

UN PALLONCINO PER SPERARE



Si ringraziano

l' Associazione Italiana

Glicogenosi,

i pazienti e le loro famiglie

per il supporto alla realizzazione

di questo progetto.

UOD Malattie Neuromuscolari e Rare

Responsabile: Moggio M, MD
Sciacco M, MD, PhD
Colombo I, MD
Peverelli L, MD
Villa L, MD

Fagiolari G, Bs
Ciscato P, BS
Napoli L, PhD
Ripolone M, PhD
Violano R, Bs
Tironi R, Bs

Valentini P, Dr. Amministrativa

UO Neurologia

Responsabile: Bresolin N, MD

Genetica e Biochimica

Responsabile: Comi GP, MD

Pagliarani S, PhD
Lucchiari S, PhD
Ulzi G, PhD
Bordoni A, BS
Fortunato F, BS

Fondazione IRCCS Ca' Granda
Ospedale Maggiore Policlinico-Università degli Studi di Milano

Cuore: nonostante il marcato aumento di glicogeno non si nota ipertrofia o alterazione delle fibre

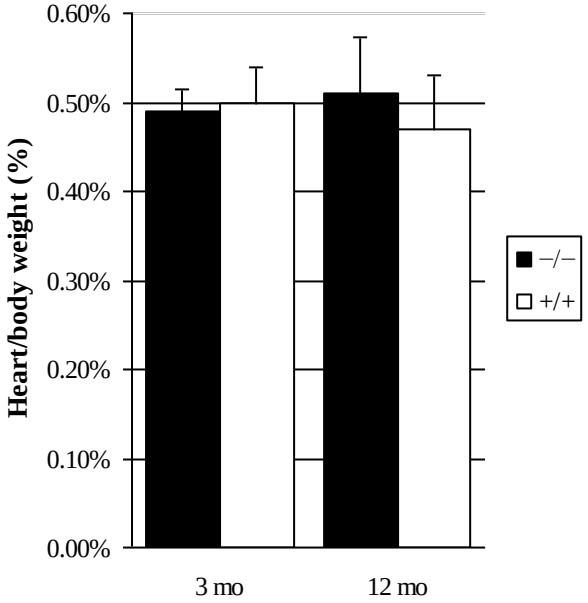

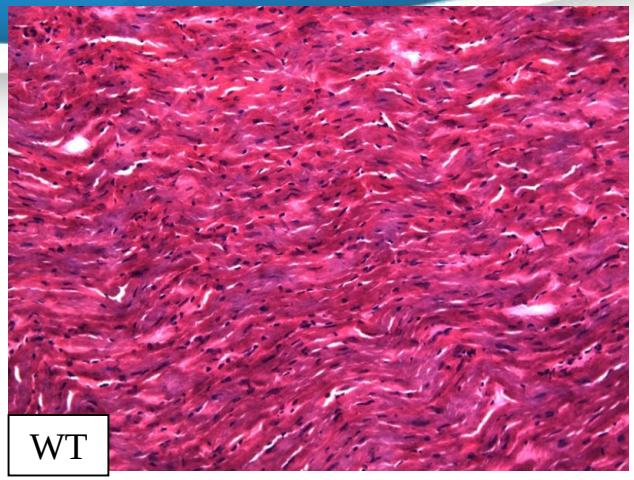

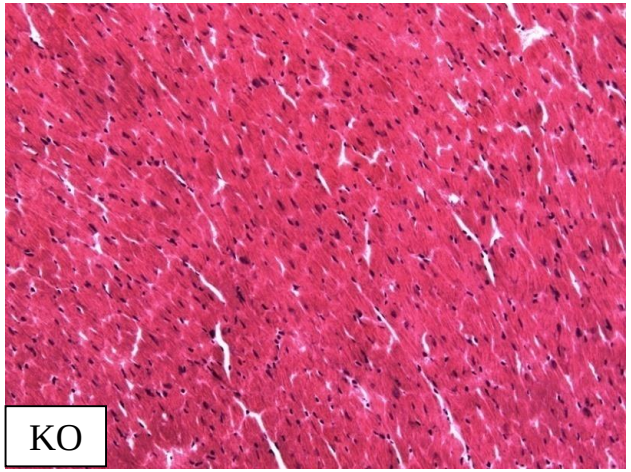

Colorazione Ematossilina-Eosina
Scale bar: — 25 µm